

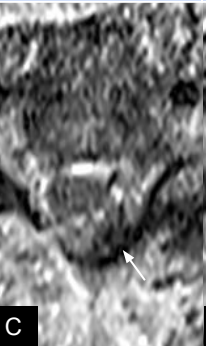



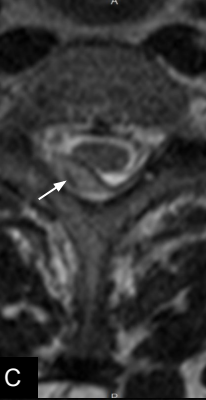
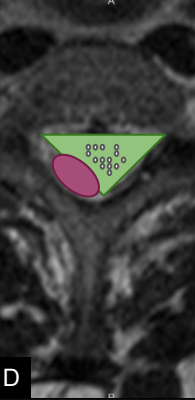


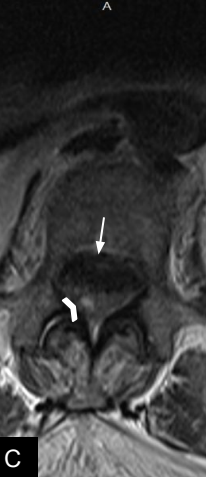
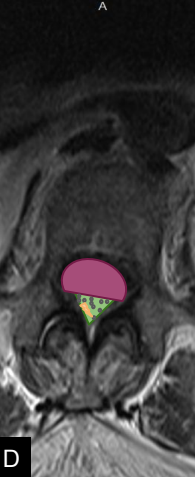

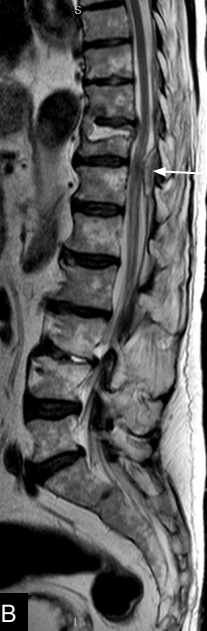
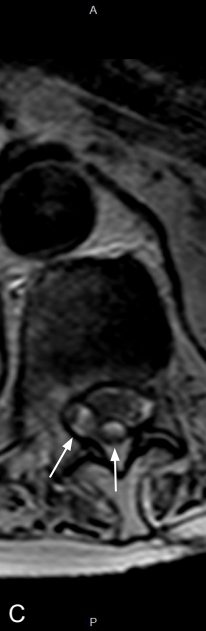
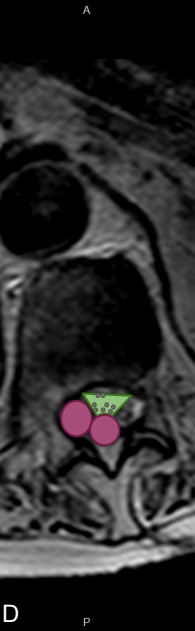

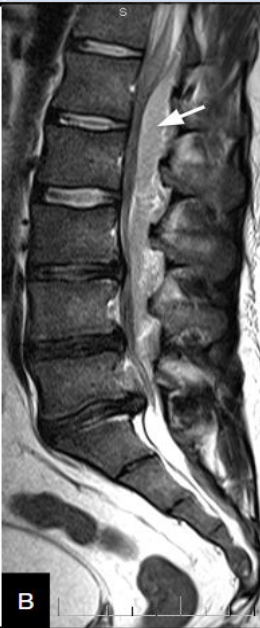









ESTADÍO	SAGITAL T1	SAGITAL T2	AXIAL T2	ESQUEMA
HIPERAGUDO				
T1: Isointenso				
T2: Hiperintenso				
Oxy-Hb				
AGUDO				
T1: Isointenso				
T2: Heterogéneo				
Deoxy-Hb				
SUBAGUDO PRECOZ				
T1: Hiperintenso				
T2: Hipointenso				
Meta-Hb Intracelular				
SUBAGUDO TARDÍO				
T1: Iso/hiperintensa				
T2: Hiperintensa				
Meta-Hb Extracelular				

ESTADÍO	SAGITAL T1	SAGITAL T2	CONTRASTE
ABSCESO EPIDURAL			
T1: Hipointenso			
T2: Hipointenso			
Realce parietal			
	A	B	C
ABSCESOS EPIDURALES			
T1: Hipointenso			
T2: Hipointenso			
Realce parietal			
	A	B	C
TUMOR EPIDURAL			
T1: Hipointenso			
T2: Isointenso			
Realce			
	A	B	C